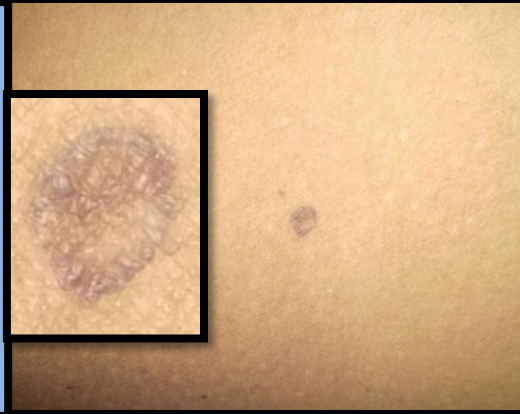

# Poster ID 50: Disseminated superficial porokeratosis with dermal amyloid deposits-a case report

Dr Gopikrishnan Anjaneyan, Dr Malini Eapen , Dermatology & Pathology Depts, Amrita Instt of Medical Sciences, Kochi

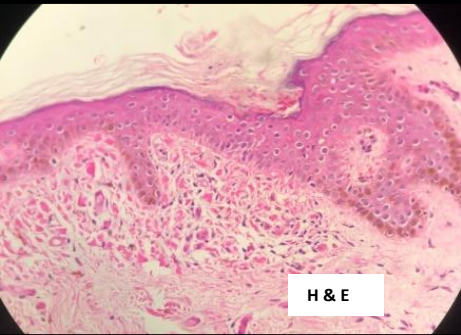
## Introduction

In 1937, Andrews first described Disseminated superficial porokeratosis (DSP) and introduced this term to indicate a clinical variant of Mibelli's porokeratosis. 2 types of localized cutaneous amyloidosis (LCA) are described: primary which includes macular and lichen amyloidosis), and secondary LCA, which is associated with inflammatory or neoplastic conditions. The mechanism by which DSP induces dermal amyloid deposits is not clear, but Piamphongstant et al. first suggested that this process can derive from degenerated epidermal keratinocytes

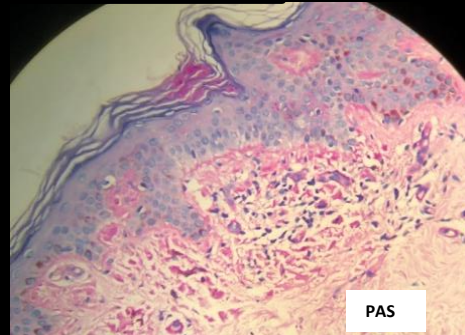


## Case Report

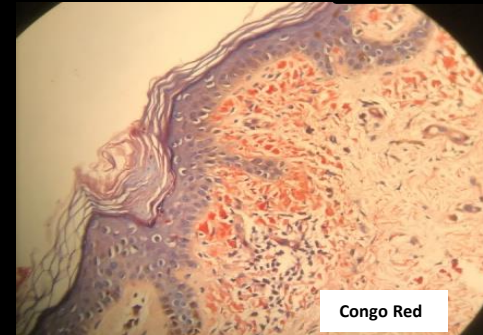
60 year old female presented with multiple asymptomatic hyperpigmented plaques over back and thighs for more than 20 years. She had no comorbidities and was not on any medications. O/e- Few scattered well defined discrete hyperpigmented slightly raised flat topped annular plaques with central clearing present over the upper limbs, thighs of size about 0.5x0.5cm. With a provisional diagnosis of disseminated superficial porokeratosis, a biopsy was taken.



H & E



PAS



Congo Red



Congo Red  
Polarised

## Histopathology

Epidermis shows basket weave keratin and plugged follicles with parakeratotic mounds resembling cornoid lamellae. Focal basal cell degeneration seen with colloid bodies in the upper dermis which is edematous and showing hyalinised vessels and pigment incontinence. PAS highlights the eosinophilic bodies . Congo red is positive under fluorescence . **Features are that of Porokeratosis with dermal amyloid deposits**

## Discussion

Very few cases of this association have been described in literature. The PAS and Congo red positivity indicates the amyloid nature of the dermal deposits. Reason for this amyloid substance in DSAP is not clear. Touart et al suggested necrotic keratinocytes might transform into amyloid by the action of dermal macrophages and a mutant clone from keratinocytes, responsible for induction of porokeratotic lesions, is presumed to produce this dermal amyloid. Amantea et al suggested a causal link between the porokeratosis and the amyloidosis, as both are caused by alterations in the keratinization. Larger studies with IHC may help understanding this phenomenon and may shed further light on pathogenesis of porokeratosis and cutaneous amyloidosis.

## References

1. Piamphongstant T, Sittapairoachana D. Localized cutaneous amyloidosis in disseminated actinic porokeratosis. *J Cutan Pathol.* 1974;1:207–210.
2. Touart DM, San P. Cutaneous deposition disease. *J Am Acad Dermatol* 1998; 119: 375–80.
3. Amantea A, Giuliano MC, Balus L. Disseminated superficial porokeratosis with dermal amyloid deposits: case report and immunohistochemical study of amyloid. *Am J Dermatopathol* 1998; 20: 85–8.